

Urethral Diverticula in Women: Discrepancies Between Magnetic Resonance Imaging and Surgical Findings

Doreen E. Chung,* Rajveer S. Purohit, Jeffrey Girshman and Jerry G. Blaivas

From the Departments of Urology, Weill Medical College of Cornell University (DEC, RSP, JGB), Memorial Sloan-Kettering Cancer Center (DEC) and State University of New York Downstate Medical Center (JGB), and Manhattan Diagnostic Radiology (JG), New York, New York

Purpose: Some groups consider magnetic resonance imaging the gold standard to diagnose urethral diverticula with up to 100% reported sensitivity. We describe cases contradicting this paradigm and identify reasons for discrepancies.

Materials and Methods: We searched a database for women who underwent urethral diverticulum surgery from 1998 to 2008 and also underwent preoperative magnetic resonance imaging. Images were reviewed by a blinded panel of urologists and a radiologist. They came to consensus on the presence or absence, site and anatomy of urethral diverticulum or cancer, and compared operative findings. Discrepancies were classified as errors in urethral diverticulum or cancer diagnosis and errors in urethral diverticulum anatomy or site.

Results: Of 76 patients who underwent diverticulectomy 41 also underwent magnetic resonance imaging, of whom 10 (24.4%) had a discrepancy between magnetic resonance imaging and surgical findings. In 6 of these cases there were diagnosis errors and diverticula were not seen on magnetic resonance imaging in 3. One urethral diverticulum each was misdiagnosed as Bartholin's cyst and as a typical post-collagen injection appearance. A sterile abscess was incorrectly diagnosed as a urethral diverticulum. In 2 patients magnetic resonance imaging did not detect cancer within the diverticulum. A major discrepancy in anatomy made intraoperative decision making difficult in 2 patients.

Conclusions: In cases clinically suspicious for urethral diverticulum magnetic resonance imaging had a 24.4% error rate. Serious consequences are failure to detect cancer and suboptimal treatment for urethral diverticulum. The reason for the high magnetic resonance imaging accuracy rate in other series may be that in the absence of radiological confirmation some surgeons may choose not to perform surgery. Magnetic resonance imaging is useful to assess urethral diverticula but physicians should be aware of its limitations.

Abbreviations and Acronyms

CT = computerized tomography

LUTS = lower urinary tract symptoms

MRI = magnetic resonance imaging

UD = urethral diverticulum

VCUG = voiding cystourethrogram

Submitted for publication October 20, 2009.

* Correspondence: Department of Urology, Weill Cornell Medical College and Memorial Sloan-Kettering Cancer Center, 525 East 68th St., Box 261, Suite F-9 West, New York, New York 10065 (telephone: 212-746-4811; FAX: 212-746-5329; e-mail: doreenechung@gmail.com).

Key Words: urethra, diverticulum, magnetic resonance imaging, diagnostic imaging, diagnostic errors

URETHRAL diverticula are not uncommon. The prevalence in unselected patients is 0.006% to 3%.¹⁻³ In women with LUTS the published prevalence is between 1.4% and 10%.^{3,4} In our unreported experience with more than 9,000 videourodynamic studies in women with LUTS the prevalence was no more than 0.3%. The most commonly re-

ported symptoms at presentation are nonspecific LUTS, particularly overactive bladder, pain and infection.^{5,6} Presentation may vary highly, resulting in diagnostic difficulty.⁷ Some groups regard MRI as the gold standard for UD diagnosis with 100% reported detection sensitivity.^{8,9} Imaging has an important role in diagnosis

and preoperative planning. Imaging also aids in evaluating UD complicating features, such as abscess, cancer and other conditions, including endometriosis. Stones may form within UDs but are not easily detected by MRI.

UD are most commonly reported in the posterior wall of the mid urethra,^{10–12} although they may involve any part of the urethral circumference. Large UDs may wrap around the urethra in a horse-shoe configuration. On MRI UDs are most evident on T2-weighted sequences as hyperintense lesions adjacent to or surrounding the urethra.¹³ Definitive diagnosis can be made when communication is visualized between urethra and UD but a communication is not usually seen due to its small size.

Studies suggest that MRI can increase UD detection and alter surgical management. Foster et al retrospectively reviewed the records of 27 women who underwent surgery for UD, of whom 21 also underwent preoperative MRI.¹⁴ Management was altered based on MRI in 4 women. Lorenzo et al retrospectively reviewed a series of 140 patients who presented with LUTS and underwent endorectal coil MRI as part of evaluation.⁴ Of the patients 10% had UD diagnosed only by MRI. They concluded that endorectal coil MRI likely has a role in evaluating women with symptoms difficult to explain by other diagnostic modalities.

Some retrospective studies show that MRI is 100% accurate to diagnose UD but Kim et al found only 70% MRI sensitivity to diagnose UD.¹⁵ In our experience MRI was potentially misleading in diagnosis and in preoperatively determining UD anatomical features. We describe cases in which preoperative MRI provided misleading diagnostic or

anatomical information on UD. A further objective was to identify reasons for the discrepancies.

MATERIALS AND METHODS

We searched a database for all women who underwent surgery for UD and preoperative MRI from 1998 to 2008. Indications for surgery were symptoms consistent with UD as well as findings on physical examination, VCUG, computerized tomography, MRI and transvaginal ultrasound. Patients were scanned on a 1.5 Tesla scanner with between 3 and 4 mm slice thickness, between 24 and 33 cm field of view and 256 × 160 matrix using a torso phased array coil. In plane resolution was between 1 and 1.3 mm. Multiplanar multisequence imaging included T1 and T2-weighted sequences with and without fat saturation, and pre-administration and post-administration intravenous gadolinium contrast medium. Images were stored as digital images and communications in medicine images and reviewed on picture archiving and communication system workstation by a radiologist trained to interpret pelvic MRI. We (1 radiologist and 2 urologists) reviewed MRI images in blinded fashion. The panel came to a consensus on the presence or absence of UD or cancer, and UD site and anatomy. The consensus position was then compared to the MRI report, intraoperative findings described in the operative note and surgeon discussion. Discrepancies in MRI and surgical findings were classified as errors in detecting UD, errors in UD anatomy or site and failure to detect cancer.

RESULTS

We identified 77 patients, of whom 41 underwent MRI within 1 month before surgery, including 10 (24.4%) with a substantial discrepancy between MRI and surgical findings. In 6 patients (14.6%) MRI did not accurately diagnose UD (see [table](#)). In a subset

Discrepancies between MRI and surgical findings

Pt No.	Error Type	MRI	Intraop VCUG or Other Radiographic Findings	Disparity Reason
1	Innaccurate diagnosis	No findings suggested UD	2 cm UD on VCUG	UD may have been full of debris or collapsed at MRI
2	Innaccurate diagnosis	No findings suggested UD	2 cm Distal UD filled with fluid, thick walled + loculated on CT for flank pain	UD may have been filled with calcium, air or blood
3	Innaccurate diagnosis	No findings suggested UD	5 mm Obvious UD on physical examination near meatus	Tic may have been too small to detect or not filled at MRI
4	Innaccurate diagnosis	Bartholin's gland cyst	Distal urethral UD	Distal, lat UD
5	Innaccurate diagnosis	Periurethral mass filled with large amount of proteinacious material, collagen injection?	UD with wide connection to urethra filled with pus	Pus may have made UD difficult to diagnose + made appearance on T2 dark
6	Innaccurate diagnosis or site error	UD	Hourglass-shaped sterile noncommunicating abscess parallel to urethra	Bright coaptite T2 signal on T2 imaging was thought to be fluid
7	Anatomy or site error	C-shaped 2 cm UD 6 mm distal to bladder neck	Multiloculated, thick 4 cm UD, 2 cm opening	Configuration change between OR operation + MRI?
8	Anatomy or site error	Mid to distal urethral UD	Circumferential UD from bladder neck to distal urethra	UD may have become more extensive between imaging + operation
9	Failed to detect Ca	UD	Urethral Ca (adenoca)	Inadequate MRI sensitivity
10	Failed to detect Ca	UD	Urethral Ca (squamous cell Ca), 5 mm mass adjacent to UD	Inadequate MRI sensitivity

of 3 of these patients (7.3%) UD was not seen on MRI (fig. 1, A and B). One UD was misdiagnosed as Bartholin's cyst due to its unusual distal, lateral site (fig. 2, A). A patient with a sterile abscess was incorrectly diagnosed with UD (fig. 1, C). Another patient with LUTS who had UD based on physical examination findings was incorrectly diagnosed by MRI with a urethra with a typical post-collagen injection appearance. In 2 patients (4.9%) there was a major discrepancy in UD site or anatomy that made intraoperative decision making difficult (see

table). At operation the UD were substantially different in size and configuration than on MRI (fig. 2, B). Thus, decision making became challenging in terms of dissection and excision extent and direction. Two patients (4.9%) were diagnosed with cancer (squamous cell carcinoma and adenocarcinoma in 1 each) within the UD by palpation in the operating room but had no suspicious findings on preoperative MRI (see table and fig. 2, C). In each case the only abnormality was UD wall hardness and thickness. No discrete mass was noted. Each patient had

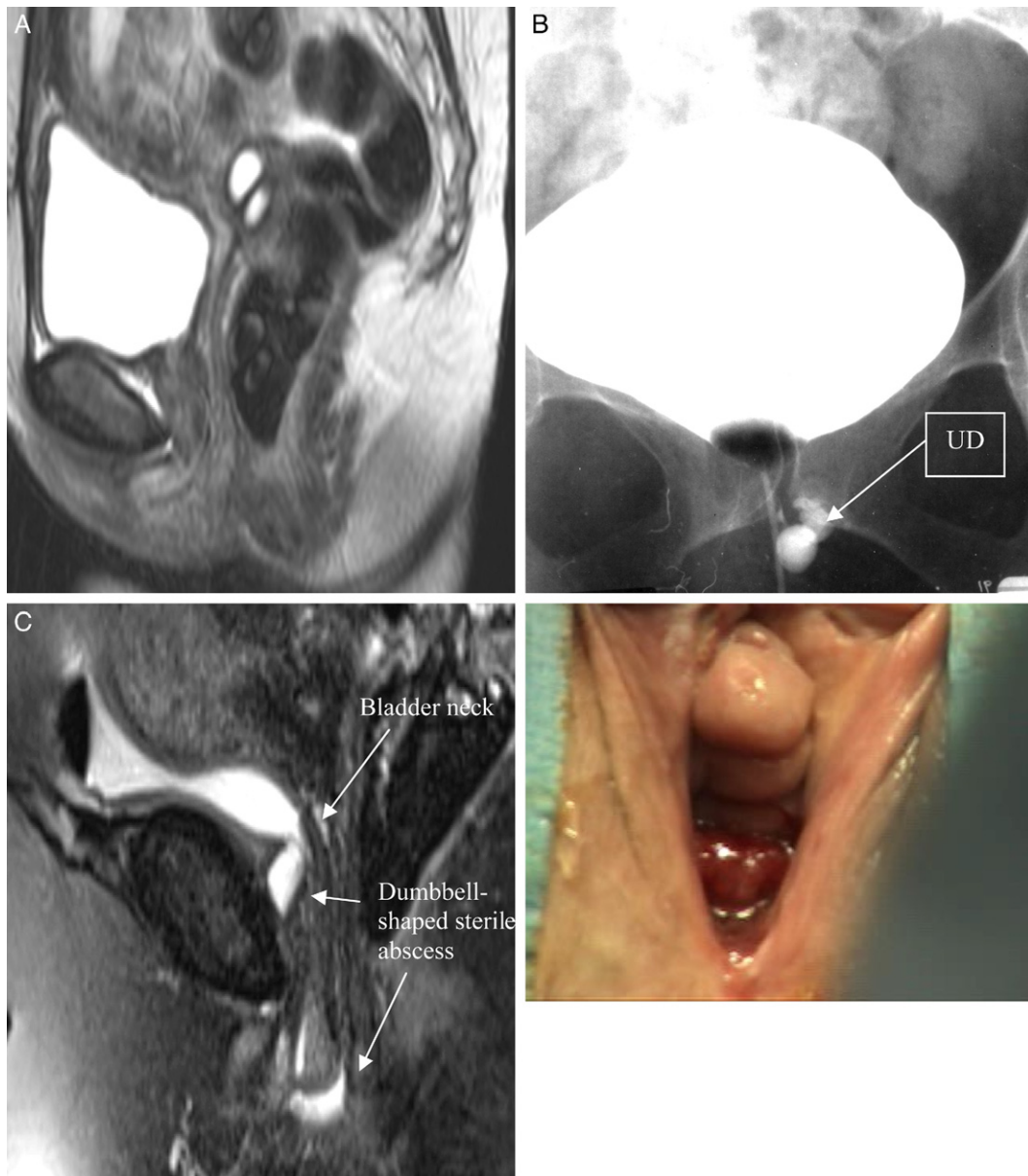

Figure 1. Inaccurate UD diagnosis. A and B, in patient 1 UD was obvious at operation and on VCUG but no MRI findings caused UD suspicion, perhaps due to lack of contrast medium. A, MRI. B, VCUG shows anterior vaginal wall, similar to surgical view. C, patient 17 was diagnosed with UD by MRI but had dumbbell-shaped sterile abscess. No communication with urethra was seen and cavity was filled with thick white urethral bulking agent fluid. When abscess proximal portion was compressed with finger, distal portion protruding from meatus became tense.

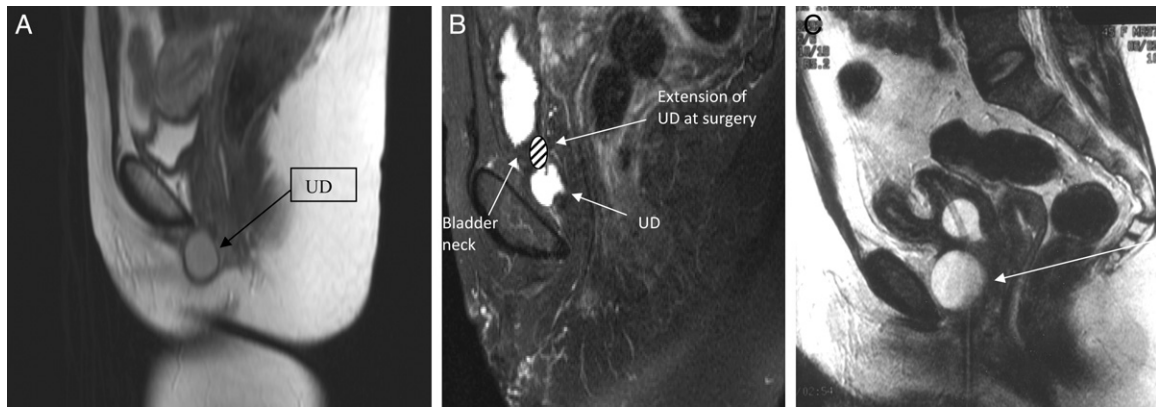


Figure 2. A, inaccurate UD diagnosis in patient 6 with UD diagnosed with Bartholin's cyst on MRI. At operation lesion looked like simple vaginal wall inclusion cyst 1 cm lateral and proximal to urethral meatus. It was easily noted, thick-walled and bluish-white. B, preoperative MRI reveals error in anatomy/position in patient with 4 cm multiloculated, thick UD spanning entire urethral length. MRI shows 2 cm C-shaped UD distal to bladder neck. C, failure to detect squamous cell carcinoma within diverticulum (arrow).

extensive UD wall involvement with cancer. In the woman with adenocarcinoma all margins were positive despite what appeared to be complete removal.

DISCUSSION

The literature is not extensive but other groups have reported almost 100% MRI sensitivity to diagnose UD. Foster et al performed MRI in 21 patients with a clinical diagnosis of UD before surgery and UD was detected on MRI in all.¹⁵ In 4 patients MRI findings changed treatment. One patient had a diverticular filling defect on MRI, which proved to be urethral adenocarcinoma. She was treated with cystourethrectomy. In 3 patients UD was diagnosed by MRI but not detected by other imaging techniques. Since they only operated in patients with radiological confirmation of the diagnosis, treatment was altered in these 3 patients due to MRI findings. Blander et al retrospectively reviewed a series of 27 patients with suspected UD who underwent endoluminal (endorectal or endovaginal) MRI, including 20 with surgical repair.⁸ In all cases MRI and surgical findings agreed. In contrast to these studies, Kim et al performed MRI in 20 patients who underwent surgery for UD.¹⁵ In 14 patients UD was identified correctly before surgery (70% sensitivity).

Despite prior data we believe that the decision to operate in patients with LUTS for possible UD is multifactorial and MRI findings should be interpreted in the context of patient symptoms, examination and other radiographic tests. In our retrospective study 24.4% of cases clinically suspicious for UD had a major discrepancy between MRI and surgical findings. In 6 patients MRI failed to accurately diagnose UD before surgery. Clinical suspicion of UD by experienced surgeons based on history, physical exam-

ination or other radiographic studies was high in these patients and, hence, they were still brought to the operating room. Had we relied completely on MRI findings 3 patients would have been denied surgery.

There are several explanations for these diagnostic errors. UD was not diagnosed accurately on MRI because the lesions did not appear fluid filled on T2-weighted imaging. UDs are dynamic by nature and some constantly fluctuate in size. A limitation of MRI is that it captures images at a single point in time, in contrast to more dynamic tests that capture real-time images, such as VCUG. The differential diagnosis of a dark cavity on T2-weighted MRI includes long-standing blood, calcium and air. At imaging these lesions may be filled with blood or debris, making the diagnosis difficult. One patient in whom MRI showed a urethra with the typical appearance after collagen injection had a UD filled with pus at surgery. Other potential reasons for failed diagnosis are size too small for MRI sensitivity and UD loss of fluid.

Bartholin's gland cyst was diagnosed in 1 case of UD due to the unusual distal site of UD and inability to identify urethra-lesion communication. Fluid may not always be present in a small connection between the UD and the urethra, making it difficult to detect communication. In this case the incorrect diagnosis may have had adverse consequences since the surgeon may have chosen to excise the lesion on an outpatient basis and, thus, would not have had the tools or equipment needed for subsequent urethral reconstruction.

Accurate delineation of UD size and extent can be important to plan operative reconstruction and repair. In our series 4 patients had a discrepancy between anatomical and position results between MRI and operative findings, complicating intraoper-

ative decision making. One patient had a thick, large, multiloculated UD, which was not revealed on MRI. Had we relied only on MRI findings the UD may have been inadequately treated. Another patient appeared to have a 2 cm simple distal diverticulum that was far more extensive at operation. It was circumferential and involved the entire urethral length. In this sexually active woman a simple operation was discussed and planned. Had the true extent of the UD been known a more extensive preoperative discussion would have occurred to include more potential surgical complications and risks.

In contrast to the findings of Foster et al¹⁴ and of most serious consequence, 2 patients preoperatively diagnosed with UD on MRI had urethral carcinoma at surgery. Certain characteristics of these cancers made them difficult to diagnose by MRI. They were in the UD wall and did not project into the lumen or enhance with gadolinium. As noted by Thomas et al, there may be an association between neoplasm or neoplastic alterations and UD.¹⁶ They reviewed the pathology specimens of 90 women who underwent urethral diverticulectomy and found neoplastic alterations in 5 (6%). Another 3 patients (3%) had high grade dysplasia. Dalbagni et al reported that 5-year

disease specific survival for urethral carcinoma in women was 71% for distal lesions, 48% for proximal lesions and 24% for lesions involving most of the urethra.¹⁷ Preoperative diagnosis of urethral carcinoma in these 2 patients would have allowed us to engage in more thorough preoperative counseling and in planning more complete tumor excision.

Possible sources of error in our study are small sample size, its retrospective nature and time from MRI to surgery. Also, recently many groups have used endoluminal MRI,^{4,8} which is believed to have greater sensitivity, while we did not. However, not all radiology centers that urologists refer to can provide endoluminal MRI. The high accuracy rate of MRI in other series may be due in part to the fact that in the absence of radiological confirmation, especially for small UDs, some surgeons may choose not to perform surgery.

CONCLUSIONS

In our series of cases clinically suspicious for UD MRI had a 24% diagnostic error rate. Serious consequences are failure to detect cancer and suboptimal UD treatment. MRI is useful to evaluate UD but physicians should be aware of its limitations.

REFERENCES

1. Bruning E: Die Pathologie der weiblichen Urethra und des Parurethrium. Stuttgart: Enke 1959.
2. Andersen M: The incidence of diverticula in the female urethra. *J Urol* 1967; **98**: 96.
3. Aldridge JC, Beaton J and Nanzig R: A review of office urethroscopy and cystometry. *Am J Obstet Gynecol* 1978; **131**: 432.
4. Lorenzo A, Zimmern P, Lemack G et al: Endorectal coil magnetic resonance imaging for diagnosis of urethral and periurethral pathologic findings in women. *Urology* 2003; **61**: 1129.
5. Davis H and TeLinde R: Urethral diverticula: an assay of 121 cases. *J Urol* 1958; **80**: 34.
6. Leach G, Schmidbauer H, Hadley H et al: Surgical treatment of female urethral diverticulum. *Semin Urol* 1986; **4**: 33.
7. Romanzi L, Groutz A and Blaivas J: Urethral diverticulum in women: diverse presentations resulting in diagnostic delay and mismanagement. *J Urol* 2000; **164**: 428.
8. Blander D, Rovner E, Schnall M et al: Endoluminal magnetic resonance imaging in the evaluation of urethral diverticula in women. *Urology* 2001; **57**: 660.
9. Ockrim J, Allen D, Shah P et al: A tertiary experience of urethral diverticulectomy: diagnosis, imaging and surgical outcomes. *BJU Int* 2009; **103**: 1550.
10. Hoffman M and Adams W: Recognition and repair of urethral diverticula: a report of 60 cases. *Am J Obstet Gynecol* 1965; **92**: 106.
11. Leach G, Sirls L, Ganabathi K et al: L N S C3: a proposed classification system for female urethral diverticula. *Neurourol Urodyn* 1993; **12**: 523.
12. Pavlica P, Viglietta G, Losinno F et al: I diverticoli dell'uretra femminile: studio radiologico ed ecografico. *Radiol Med* 1988; **75**: 521.
13. Hahn W, Israel G and Lee V: MRI of female urethral and periurethral disorders. *AJR Am J Roentgenol* 2004; **182**: 677.
14. Foster R, Amundsen C and Webster G: The utility of magnetic resonance imaging for diagnosis and surgical planning before transvaginal periurethral diverticulectomy in women. *Int Urogynecol J Pelvic Floor Dysfunct* 2007; **18**: 315.
15. Kim B, Hricak H and Tanagho E: Diagnosis of urethral diverticula in women: value of MR imaging. *AJR Am J Roentgenol* 1993; **161**: 809.
16. Thomas A, Rackley R, Lee U et al: Urethral diverticula in 90 patients a study with emphasis on neoplastic alterations. *J Urol* 2008; **180**: 2463.
17. Dalbagni G, Zhang Z, Lacombe L et al: Female urethral carcinoma: an analysis of treatment outcome and a plea for a standardized management strategy. *Br J Urol* 1998; **82**: 835.